



**Original Research**

**Intra osseous transmigration of mandibular canines – A  
report of two cases**

*Nagaveni N B<sup>1</sup>, Poornima P<sup>2</sup>, Gouri R Reddy<sup>3</sup>, Yashwanth Sreedhara<sup>4</sup>*

*<sup>1</sup>Professor, <sup>2</sup>Professor and Head, <sup>3,4</sup> Post graduate, Department of Pediatric and Preventive Dentistry, College of Dental Sciences, Davangere, Karnataka, India.*

**How to cite:** Nagaveni N B et al. Transmigration of mandibular canines. *Int J Ped Rehab* 2022; 7(1):1-10.

Received : 25.03.2022

Accepted: 21.05.2022

Web Published: 30.06.2022

**Abstract**

**Background:**

A canine is classified as "transmigrated" when it crosses the midline. Transmigration of mandibular canines bilaterally is an extremely rare developmental dental ectopia with obscure etiology.

**Case Description:**

A 13 year old female and 10 year old male patient reported to the department with the chief complaint of missing teeth in the upper front teeth region and retained deciduous tooth in the lower front teeth region respectively. Panoramic radiographs revealed horizontally impacted permanent mandibular canines crossing the midline and located below the apices of the incisors. Based on the clinical, radiographic and CBCT findings, a diagnosis of transmigration of mandibular canines was established.

**Conclusion:**

Dental anomalies and pathologies such as cystic lesions, odontoma and root resorption of the adjacent teeth have been reported to be associated with transmigrated canines. Early diagnosis by radiographic evaluation and correction either by orthodontic intervention or by surgical transplantation is important to protect oral structures and preserve the canines to ensure facial harmony and improved function.

**Keywords:** *Bilateral; Mandibular canine; Transmigration; Unilateral;*

---

**Address for Correspondence:**

Nagaveni N B

Department of Pediatric and Preventive Dentistry

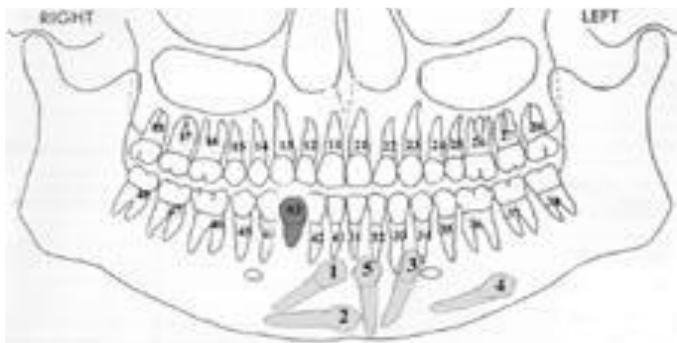
College of Dental Sciences

Davangere-577004, Karnataka, India.

E-mail: [nagavenianurag@gmail.com](mailto:nagavenianurag@gmail.com)

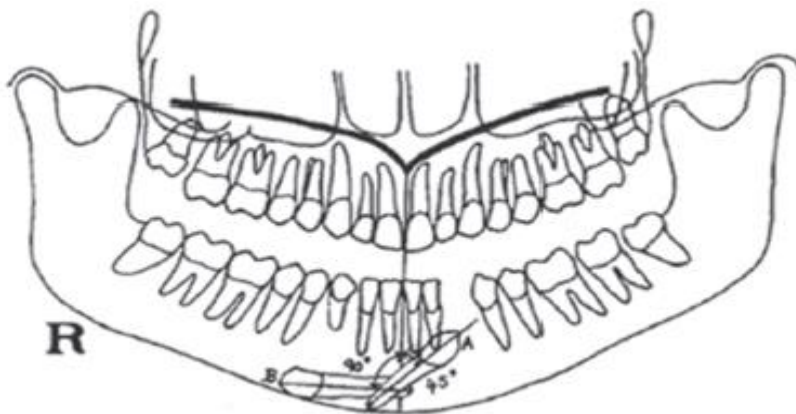
## INTRODUCTION

Lack of eruption of the mandibular canine is a rare occurrence. The unerupted tooth sometimes tends to migrate to a location away from the site of development, but it usually stays within the same quadrant. The permanent mandibular canine is the only tooth which is reported to have migrated across the midline<sup>[1]</sup>. Such pre-eruptive migration of impacted tooth across the midline is a rare developmental dental anomaly and is termed as transmigration. Transmigration of permanent mandibular canine is particularly significant due to aesthetic and functional reason<sup>[2]</sup>. The intraosseous migration of impacted teeth is an unusual developmental dental anomaly; with obscure etiology<sup>[3]</sup>. Figure 1 and Figure 2 depicts the pattern of unilateral and bilateral transmigration of canines.



**Figure 1: Patterns of unilaterally transmigrating mandibular canines**

Courtesy: Mazinis E, Zafeiriadis A, Karathanasis A, Lambrianidis T. Transmigration of impacted canines: prevalence, management and implications on tooth structure and pulp vitality of adjacent teeth. *Clin Oral Invest.* 2012;16(2):625-32.



**Figure 2: Patterns of bilaterally transmigrating mandibular canines.**

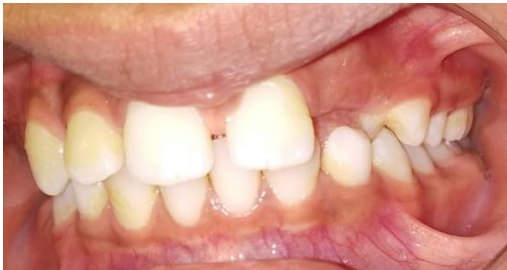Courtesy: Achint Garg, Suraj Agarwal, Shweta Agarwal, Samta Mittal, Parul Singh. "Pattern of Bilateral Transmigration of Impacted Mandibular Canines: A Radiographic Study of 3 Cases". *Journal of Evidence based Medicine and Healthcare.* 2015;2(7):921-928.

The purpose of this paper is to report two cases of intraosseous transmigration of mandibular permanent canines with emphasis on radiographic investigation for clinically missing permanent canines or over retained deciduous canines.

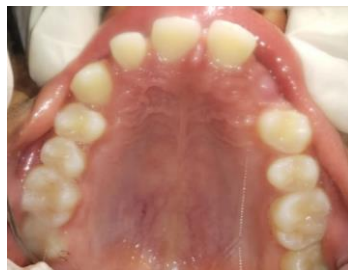## CASE REPORTS

### CASE 1:

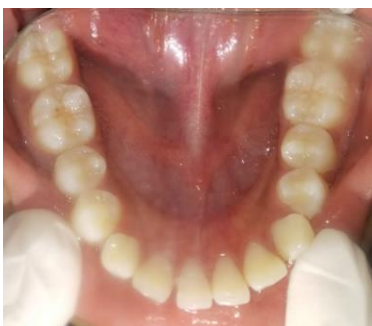A 13-year-old female patient, reported to the Department of pediatric and preventive dentistry with a chief complaint of missing teeth in the upper left front teeth region. Habit history revealed tongue thrusting. On intra oral examination, generalized maxillary spacing with clinically missing left lateral incisor and eruption bulge in the region of maxillary left canine were noticed along with proclined maxillary anteriors and high labial frenal attachment (Fig. 3) (Fig. 4). Bilaterally over retained deciduous canines and midline shift towards right side were present in the mandibular arch (Fig. 5). Radiologic evaluation of panoramic radiograph revealed congenitally missing maxillary left lateral incisor, bilateral horizontal impaction of mandibular permanent canines at the apices of mandibular permanent incisors with both the canines crossing the midline and overlying each other along half of their length but in opposite direction (Fig. 6). Based on these findings, a diagnosis of bilaterally transmigrated impacted mandibular permanent canines was made. According to Mupparapu classification for bilaterally transmigrated mandibular canines (2007), the case can be classified as Type III with Subtype A where in the canines are positioned within the symphysis region one above the other. The parents were explained about the treatment options, however, unfortunately they were not willing to undergo treatment. Therefore, an informed consent was obtained regarding the same.



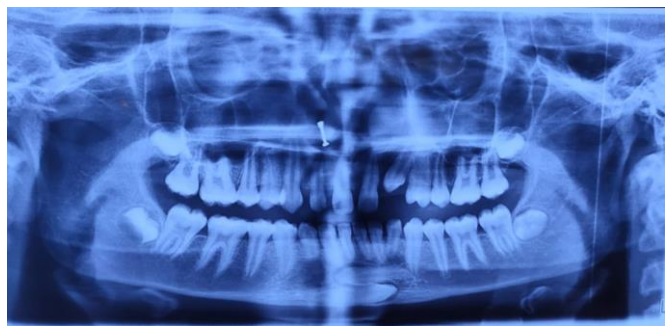**Figure 3:** Intra-oral frontal view (Case 1)



**Figure 4:** Maxillary occlusal view (Case 1)



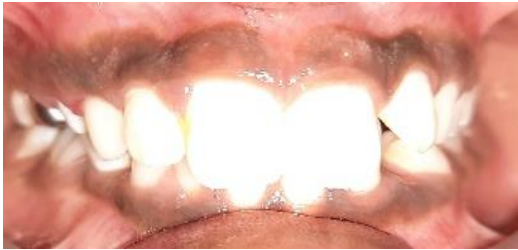**Figure 5:** Mandibular occlusal view (Case1)



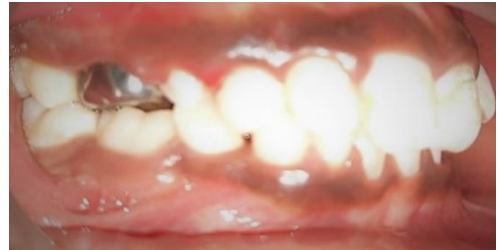**Figure 6:** OPG showing transmigrated canines (Case1)

**Case 2:**

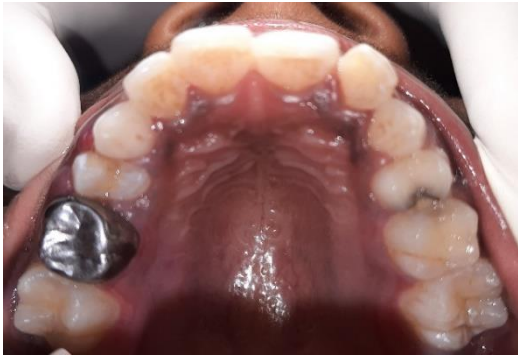A 10-year-old male patient reported to the Department of Pediatric and Preventive Dentistry with a chief complaint of retained deciduous tooth in the lower front teeth region. On intra oral examination, over retained deciduous mandibular right lateral incisor was noted. Eruption bulge was noted in the region of mandibular left canine. Stainless steel crown was present in 55 and proximal caries was present in 64 (Fig.7) (Fig.8) (Fig.9) (Fig.10). Panoramic radiograph showed horizontally impacted right permanent mandibular canine crossing the midline, placed at the apices of mandibular permanent incisors (Fig.11). CBCT findings include a) Horizontally impacted 43 (Fig.12), b) Labially placed crown tip of 43 with thinning of labial cortex (Fig.13), c) Root tip of 31 in proximity with follicular space of 43 (Fig.14). Based on these findings, the final diagnosis was unilaterally transmigrated impacted right permanent mandibular canine which is in accordance to Type II of Mupparapu classification of unilaterally transmigrating mandibular molars.



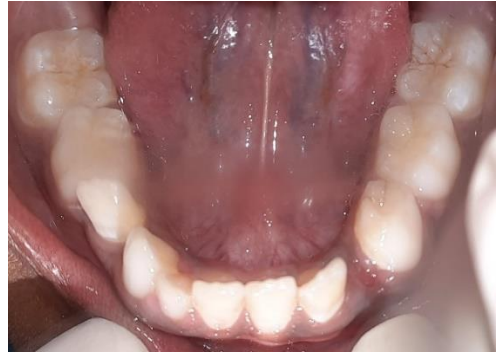**Figure 7:** Intra-oral frontal view (Case 2)



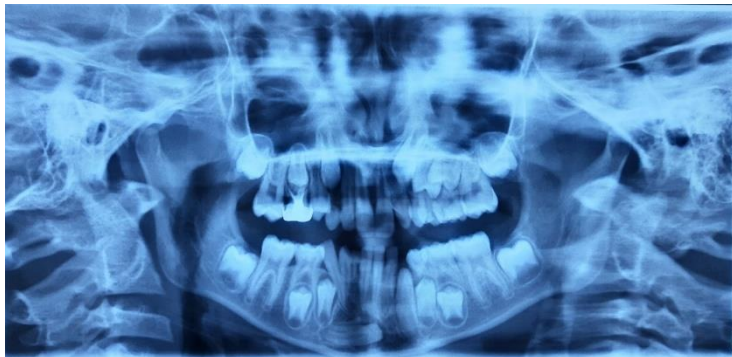**Figure 8:** Intra oral –Lateral view (Case 2)



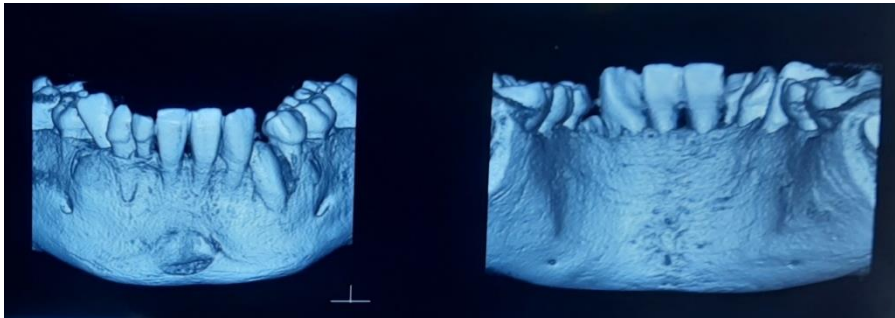
**Figure 9:** Maxillary occlusal view (Case 2)



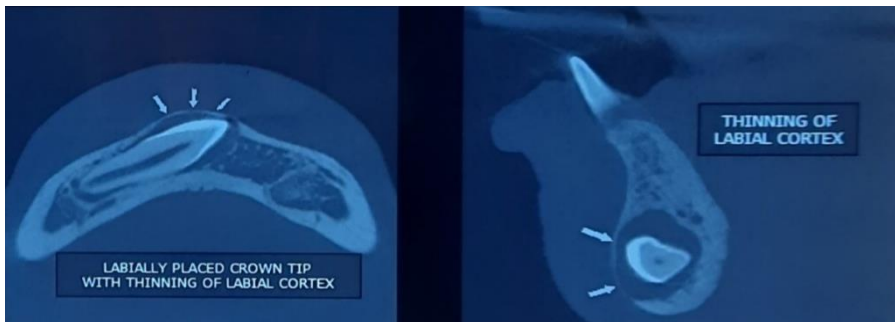
**Figure 10:** Mandibular occlusal view (Case2)



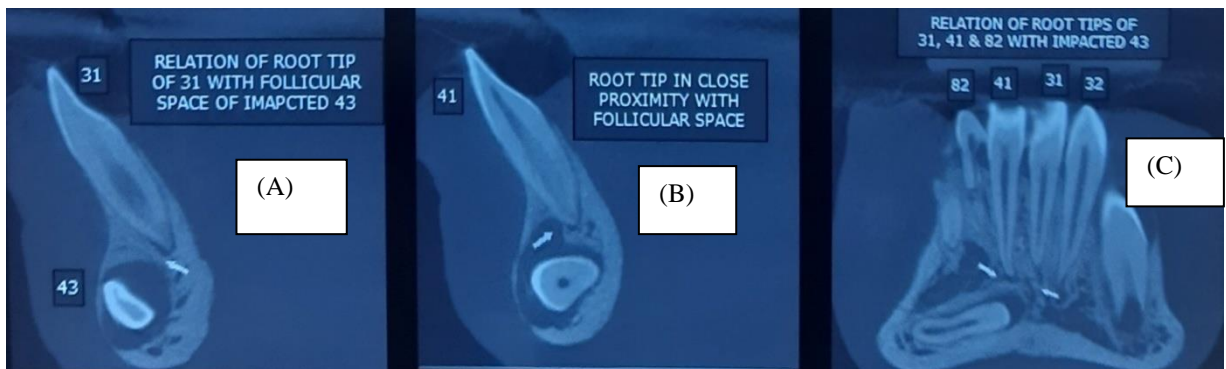
**Figure 11:** OPG showing transmigration of canine (Case2)



**Figure 12:** 3D Reconstructed images- Labial view (A), Lingual view (B) – Case 2



**Figure 13:** Thinning of labial cortex -Axial view (A), Sagittal view (B) – Case 2



**Figure 14:** Relation of root tip of 31 with follicular space of impacted 43. A, B- Sagittal view, C- Coronal view – Case 2

## DISCUSSION

The incidence of mandibular canine impaction ranges from 0.92% to 5.1%; whereas the incidence for transmigration of maxillary and mandibular canine ranges from 0.1% to 0.31% [3]. A study done in Turkish subpopulation showed that the incidence of transmigrated maxillary and mandibular canines was 0.34% and 0.14% respectively [4].

The prevalence for transmigration of unilateral canine was found to be 1.14% which is less common in mandible (0.52%) compared to that of maxilla (0.62%) [4]. The prevalence for bilateral transmigration of mandibular canines varies between 0.3-0.66% (Table 1).

Table 1: Prevalence of bilateral transmigration of canines

| S.NO. | AUTHOR & YEAR                                                              | PREVALENCE    |
|-------|----------------------------------------------------------------------------|---------------|
| 1.    | Celikoglu, et al. <sup>5</sup> 2010                                        | 0.3%          |
| 2.    | Mazinis, et al. <sup>6</sup> 2012                                          | 0.17%         |
| 3.    | Kumar S, et al. <sup>7</sup> 2012 - Orthodontic Patient population (India) | 0.46%         |
| 4.    | Tarsariya, et al. <sup>8</sup> 2015                                        | 0.14 - 0.31 % |
| 5.    | Sharma G, et al. <sup>9</sup> 2014 (North Indian population)               | 0.66%         |
| 6.    | Kamiloglu, et al. <sup>10</sup> 2014                                       | 0.44%         |

It is assumed that the mandibular canine transmigration evolves at an early age, between 6 and 8 years, which is before the completion of root formation. The accurate cause and mechanism of transmigration remains unclear <sup>[5]</sup>. Over the years various probable factors have been put forth. These include anomalous position of tooth bud, displacement of dental lamina in the embryonic life, strong eruption force, agenesis of the adjacent teeth, premature loss of deciduous teeth, retention of canines, crowding, spacing, supernumerary teeth, excessive length of crown, Inadequate eruption space, bony pathology resembling a cystic lesion, tumors, cysts, odontomas located in path of eruption, genetic role, fracture, osteodental discrepancy, displacement of the canine crypt, endocrine pathology and heredity, local trauma, oral disease, diet, intrauterine defects and idiopathic origin <sup>[6],[7]</sup>.

Pippi and Kaitsas proposed a theory to explain the pathogenesis of transmigration of canines, which included two factors: 1) the lasting root formation exerts a strong and extended eruptive force and 2) the widening of the follicular space leads to an osteolytic area peri-coronally. The combined effects of these factors can lead to anomalous intraosseous movement of the canine in the mandible. A site of least resistance, towards which the tooth migrates during root formation is represented by the osteolytic area peri-coronally which is related to the inflammatory stimuli resulting in the secretion of signal molecules. This results in the intraosseous movement of the cuspid (in the direction opposite to the root) until mechanically obstructed (cortical bone) or in cases where the peri-coronal osteolytic area has dissipated. The precise interplay of these events is speculative, and several other factors are thought to be facilitating, which includes the spongy bone tissue of the mandible <sup>[8]</sup>. Many authors, therefore believe that only mandibular canines can transmigrate, as the maxillary canines need to transmigrate through the palatine bone unlike the mandibular bone, and also the intermaxillary suture acts as a barrier against such migrations <sup>[9],[10]</sup>.

The maxillary canines are never seen to transmigrate; however, permanent mandibular cuspids are the only teeth that are reported to have migrated across the midline <sup>[11]</sup>. The incidence of which is higher in females than males (1.8:1). Transmigration usually occurs unilaterally, wherein the left canine is more commonly affected than the right (1.6:1) <sup>[12]</sup>. Transmigration of bilateral canines is exceptional. In relation to a case of bilaterally transmigrating mandibular canines, it is important to study the canines based on the projected path of eruption, eruption status and migration pattern <sup>[13]</sup>. The clinical signs in such cases include the over-retention of the deciduous canine and permanent canine failing to erupt beyond its physiological period of eruption <sup>[3]</sup>.

According to numerous authors, canine tooth germ placed anterior to the mandibular incisors might have migrated towards the contra-lateral side due to the growth of mandible, while other authors suggest that the canine had been directed to an aberrant position as a result of an abnormally strong eruptive forces <sup>[12],[13]</sup>. According to Howard, the impacted mandibular canines that lie between 25 and 30 degree in the midsagittal plane do not tend to migrate across the midline whereas those which lie between 30 and 95 degree tend to

cross the mandibular symphysis. Researchers suggested that the proclined lower incisors, greater axial inclination of the impacted canine and an enlarged symphyseal cross-sectional area of the chin might act as favorable conditions for transmigrating <sup>[13]</sup>.

In 2002, Mupparapu proposed a classification for unilateral transmigrating of mandibular canine based on its path of deviation.

Table 2: Mupparapu's Classification of unilaterally transmigrating mandibular canines <sup>[13]</sup>

|        |                                                                                                                                     |
|--------|-------------------------------------------------------------------------------------------------------------------------------------|
| TYPE 1 | Canine positioned mesio-angularly across the midline, labial or lingual to the anterior teeth                                       |
| TYPE 2 | Canine horizontally impacted near the inferior border of the mandible inferior to the apices of the incisor teeth                   |
| TYPE 3 | Canine erupting on the contralateral side                                                                                           |
| TYPE 4 | Canine horizontally impacted near the inferior border of the mandible below the apices of posterior teeth on the contralateral side |
| TYPE 5 | Canine positioned vertically in the midline with the long axis of the tooth crossing the midline                                    |

However, in 2007 Mupparapu proposed a classification for bilaterally transmigrated mandibular canines. Mupparapu classification helps in better understanding, grouping transmigrations together, providing an appropriate reference point, and thereby enabling specialists to communicate more effectively, also, to formulate appropriate treatment so that the esthetic and function are restored.

Table 3: Mupparapu's classification of bilaterally transmigrating mandibular canines <sup>[13]</sup>

|           |                                                                                                                                                                                                                                                                                                                                           |
|-----------|-------------------------------------------------------------------------------------------------------------------------------------------------------------------------------------------------------------------------------------------------------------------------------------------------------------------------------------------|
| TYPE I    | Mandibular canines transmigrate across the midline, and the final position is around the midsymphiseal region with most of the crown and root portions on the opposite side of the midsagittal plane with a long axis inclination of less than 45° to the midsagittal plane                                                               |
| SUBTYPE A | Only 1 canine completely crosses the midline and the other canine is just at the midline, or both partially cross the midline                                                                                                                                                                                                             |
| SUBTYPE B | Both canines completely cross the midline                                                                                                                                                                                                                                                                                                 |
| TYPE II   | Mandibular canines transmigrate across the midline, and the final position of the canines is anywhere between the midline and the canine region of the opposite side with a long axis inclination of 45 to 90 degrees to the midsagittal plane                                                                                            |
| SUBTYPE A | Only 1 canine completely crosses the midline and the other canine is just at the midline, or both canines partially cross the midline                                                                                                                                                                                                     |
| SUBTYPE B | Both canines completely cross the midline                                                                                                                                                                                                                                                                                                 |
| TYPE III  | Mandibular canines transmigrate across the midline having a long-axis inclination of about 90 degrees. Essentially, the teeth are horizontally positioned within the body of the mandible. The final position of the both transmigratory canines may vary anywhere from the mid-symphiseal region to the opposite canine region or beyond |
| SUBTYPE A | Canines are positioned within the symphysis region, one above the other                                                                                                                                                                                                                                                                   |
| SUBTYPE B | Canines are within the body of the mandible but occupy a distant and separate position on opposite sides beyond the mid-symphiseal region, far from their ideal position within the arch                                                                                                                                                  |

Clinically, transmigrated teeth are asymptomatic and are diagnosed during routine radiographic assessment. However, neurological changes can be observed which is caused by the compression of inferior alveolar nerve by the impacted tooth and sometimes they may be found associated with pathological conditions like, pain in the lower incisors, odontomas, dentigerous cysts, the appearance of other impactions and chronic infection. Therefore, while examining a patient with over retained deciduous canine a probable diagnosis of impacted canine should be considered. Such patient should be investigated radiographically. Migrated canines usually remain impacted and they are asymptomatic or may erupt ectopically at the middle or on the opposite side of the arch. The absence or delayed eruption of permanent mandibular canines or the over retention of a primary canine in the each are common clinical findings if an impacted or transmigrated tooth for that reason most of the transmigrated canine are generally asymptomatic <sup>[14]</sup>.

Identification and diagnosis of the impacted canine and its location are the most important steps in the management of impacted canine. During the clinical examination patient's age and dentition should be correlated to determine eruption is occurring according to the chronology or not. During normal eruption of the mandibular canine, usually a labial bulge is noted on the mucosa inferior to the mandibular primary canine. When such a bulge is not visible, an intraoral palpation is required to get a clear localization of the permanent canine. Also mobility of all present teeth should be assessed during Palpation. The accurate location can be partially obtained from conventional radiographs as the first step which includes periapical radiographs, occlusal films, and panoramic (OPG) views and cone beam computed tomography (CBCT) is available to detect the exact location of the impacted tooth <sup>[10],[14]</sup>.

A limited treatment spectrum exists for transmigrated canines. It usually requires an interdisciplinary approach involving contributions from different departments. There are several options available such as preventive treatment, no treatment, interceptive treatment, extraction of the impacted canine, auto transplantation of the canine or surgical exposure, orthodontic alignment, waiting and control, or surgical removal and periodic radiographic follow up.

Indications for the extraction includes tenderness on palpation, close proximity of the tooth to inferior border of mandible, presence of cyst, root resorption of or inclination of the tooth adjacent to the transmigrating tooth, tooth with closed apex, overcoming the transmigrated tooth beyond the apex of the adjacent lateral incisor, dento-alveolar discrepancy requiring extractions for orthodontic alignment. Indication for orthodontic therapy includes the following: the roots of the lateral incisors are in correct position, sufficient space available for the orthodontic repositioning of the tooth, when transmigration is not beyond the apex of the lateral mandible, canine with incomplete apex formation and absence of signs of ankylosis. The most recommended treatment for transmigrant canines as mentioned in the available literature is the surgical extraction of affected tooth. However, any selected treatment option should be based on the patient's consent and the clinical situation of the impacted transmigrated canine <sup>[14],[15]</sup>. Unfortunately, in the present cases, the parents were not willing to undergo any treatment, therefore a informed consent mentioning the same was obtained.

The clinical implications of treating a case of transmigration of mandibular canines are as follows: surgical removal leaves a temporary large bony defect and is associated with risks of injury to the elements of mandibular canal and iatrogenic fracture of the mandible. Since the affected canines lie in close proximity to the roots of mandibular incisors because of which, root resorption of mandibular incisors and/or pathologic changes in relation to the canines are possible during orthodontic tooth movement. The transmigrated canine



crown is sequentially contoured so that it resembles the mandibular central incisor when it needs to be aligned at the midline itself. Such a conversion of canine into an incisor may require the removal of a substantial amount of crown structure which necessitates intentional root canal therapy followed by a crown [12]. One of the major disadvantages in such cases is that a canine guided occlusion cannot be achieved. Also, due to the narrow distance between the labial and lingual cortical plate the canine is more vulnerable for root dehiscence. In some cases, gingival recession was found on the labial side of the treated canine [16].

## CONCLUSION

Dental anomalies and pathologies such as cystic lesions, odontoma and root resorption of the adjacent teeth have been reported to be associated with transmigrated canines. Early diagnosis by radiographic evaluation followed by correction either by orthodontic intervention or by surgical transplantation is important to protect oral structures and preserve the canines to ensure facial harmony and improved function.

**Financial support and sponsorship** - Nil

**Conflicts of interest** - There are no conflicts of interest

## References:

1. Camilleri S, Scerri E. Transmigration of mandibular canines—a review of the literature and a report of five cases. *The Angle Orthodontist*. 2003;73(6):753-62.
2. Ahmad SA, Ahmad SS, Poddar RN, Masood R. Bilateral transmigration of mandibular canines: A case report and review of literature. *J Dent Med Sci*. 2013;3:56-9.
3. Díaz-Sánchez RM, Castillo-de-Oyagüe R, Serrera-Figallo MÁ, Hita-Iglesias P, Gutiérrez-Pérez JL, Torres-Lagares D. Transmigration of mandibular cuspids: review of published reports and description of nine new cases. *British Journal of Oral and Maxillofacial Surgery*. 2016;54(3):241-7.
4. Aktan AM, Kara S, Akgünlü F, Malkoç S. The incidence of canine transmigration and tooth impaction in a Turkish subpopulation. *The European Journal of Orthodontics*. 2010;32(5):575-81.
5. Celikoglu M, Kamak H, Oktay H. Investigation of transmigrated and impacted maxillary and mandibular canine teeth in an orthodontic patient population. *Journal of Oral and Maxillofacial Surgery*. 2010;68(5):1001-6.
6. Mazinis E, Zafeiriadis A, Karathanasis A, Lambrianidis T. Transmigration of impacted canines: prevalence, management and implications on tooth structure and pulp vitality of adjacent teeth. *Clinical Oral Investigations*. 2012;16(2):625-32.
7. Kumar S, Jayaswal P, Pentapati KC, Valiathan A, Kotak N. Investigation of the transmigrated canine in an orthodontic patient population. *Journal of orthodontics*. 2012;39(2):89-94.
8. Tarsariya VM, Jayam C, Parmar YS, Bandlapalli A. Unusual intrabony transmigration of mandibular canine: case series (report of 4 cases). *Case Reports*. 2015;2015:bcr2014205398.

9. Sharma G, Nagpal A. Transmigration of mandibular canine: report of four cases and review of literature. *Case reports in dentistry*. 2011;2011
10. Kamiloglu B, Kelahmet U. Prevalence of impacted and transmigrated canine teeth in a Cypriot orthodontic population in the Northern Cyprus area. *BMC Research notes*. 2014;7(1):1-6.
11. Koç A, Kaya S, Abdulsalam WA. Three-Dimensional Analysis of Impacted Maxillary and Mandibular Canines and Evaluation of Factors Associated With Transmigration on Cone-Beam Computed Tomography Images. *Journal of Oral and Maxillofacial Surgery*. 2021;79(3):538-e1.
12. Vuchkova J, Farah CS. Canine transmigration: comprehensive literature review and report of 4 new Australian cases. *Oral Surgery, Oral Medicine, Oral Pathology, Oral Radiology, and Endodontology*. 2010;109(4):e46-53.
13. Achint Garg, Suraj Agarwal, Shweta Agarwal, Samta Mittal, Parul Singh. "Pattern of Bilateral Transmigration of Impacted Mandibular Canines: A Radiographic Study of 3 Cases". *Journal of Evidence based Medicine and Healthcare*. 2015; 2(7): 921-928
14. Pinto L, Mengoni G, Ruscica C, Gastaldi G, Vinci R. Transmigration of a mandibular canine: case report. *Journal of Osseointegration*. 2020;12(3):236-40
15. Mahabob MN. Transmigration of mandibular cuspids: Review of literature. *Int J Oral Care Res* 2020;8:88-90.
16. Pinto PM, Naik VR, Pai V, Jadhav KS, Revankar S. Transmigration of mandibular canines-Clinical implications. *Indian J Dent Adv*. 2015;7(3):212-6.



Published by MM Publishers  
<https://www.mmpubl.com/ijpedor>

This is an open access journal, and articles are distributed under the terms of the Creative Commons Attribution-NonCommercial 4.0 International License, which allows others to remix, tweak, and build upon the work non-commercially, as long as appropriate credit is given and the new creations are licensed under the identical terms.

To view a copy of this license, visit <http://creativecommons.org/licenses/by-nc/4.0/> or send a letter to Creative Commons, PO Box 1866, Mountain View, CA 94042, USA.