

Clinical Tip

Simple innovative “V” clips for bonded lingual retainer

ABSTRACT

Retention is necessary in maximum number of orthodontic cases. Various retainers such as Hawley's retainer, Essix retainer, and bonded lingual retainers are fabricated for this purpose. However, fixed lingual retainers are the appliance of choice in cases needing permanent retention. Various techniques have been used for holding the fixed retainer in place before bonding. These techniques had a disadvantage of needing assistance for the purpose of holding the retainer in place. In some techniques, the ligature wire used to hold the retainer could cause trauma to the soft tissue if not taken due care. In this article, we are describing a new simple technique for holding the retainer. The “V” retainer clips described are easy to fabricate and place, use natural interdental space for its retention, needing less chairside time, and eliminate the need of the assistance.

Keywords: Bonded fixed retainer, long-term retention, retention

INTRODUCTION

Retention is usually necessary following orthodontic treatment to overcome the elastic recoil of the periodontal supporting fibers and to allow remodeling of the alveolar bone. The degree of change is variable and largely unpredictable. Bonded lingual retainers have been shown to be an effective means of retaining aligned anterior teeth in long-term and to avoid any relapse tendencies.^[1,2] Three generations of bonded retainers are used in orthodontics for retention purpose.^[3,4]

Various techniques have been used for fixed retention in the past such as silicone-based impression which needs laboratory support, elastics, ligatures, and dental floss which are many times tedious to use. Hence to overcome the shortcomings of these techniques here, we came up with a simple technique of placing fixed retainer where less chairside and working time is needed.

The purpose of this paper is to introduce a new technique of fixing the lingual bonded retainer at the chairside without the need for laboratory procedures or prefabricated wires. The technique presented here for stabilizing the retainer wire before bonding provides good stabilization, adaptation,

and proper positioning of the retainer wire while eliminating contamination of etched surfaces which might occur during wire positioning before bonding. The design of the spring is simple and easy to fabricate. The technique describes step-wise placement of a lower bonded retainer. A few minutes' procedure will be better accepted by the patient in comparison to a fixed appliance bonding.

STEPS IN FABRICATION


0.018” AJ Wilcock Stainless steel (SS) wire was used. The AJW archwire is basically high-tensile SS wire that is heat treated to yield excellent clinical properties.^[5]

A small round bend is given in AJ Wilcock SS wire which will rest in embrasure area between the two teeth.

CHARUSHILA VINAY CHAUDHARI, SUCHITA SADASHIV DAOKAR, SHEETAL SURAJ YAMYAR

Department of Orthodontics, CSMSS Dental College and Hospital, Aurangabad, Maharashtra, India

Address for correspondence: Dr. Charushila Vinay Chaudhari, Department of Orthodontics, CSMSS Dental College and Hospital, Aurangabad, Maharashtra, India.
E-mail: charu0015@gmail.com

Access this article online	
Website: www.orthodrehab.org	Quick Response Code 
DOI: 10.4103/ijor.ijor_14_18	

This is an open access journal, and articles are distributed under the terms of the Creative Commons Attribution-NonCommercial-ShareAlike 4.0 License, which allows others to remix, tweak, and build upon the work non-commercially, as long as appropriate credit is given and the new creations are licensed under the identical terms.

For reprints contact: reprints@medknow.com

How to cite this article: Chaudhari CV, Daokar SS, Yamyar SS. Simple Innovative “V” clips for bonded lingual retainer. *Int J Orthod Rehabil* 2018;9:130-1.

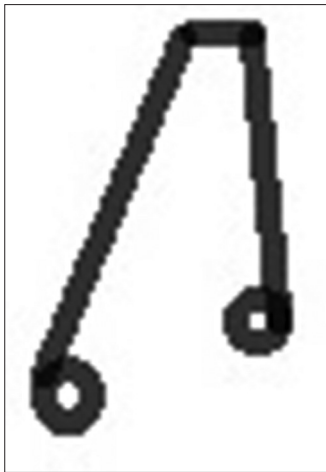


Figure 1: "V" clip

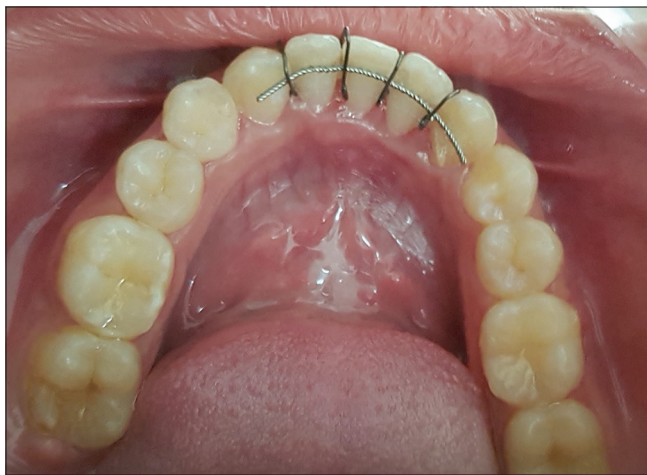

Figure 2: "V" clip in position holding the retainer before bonding

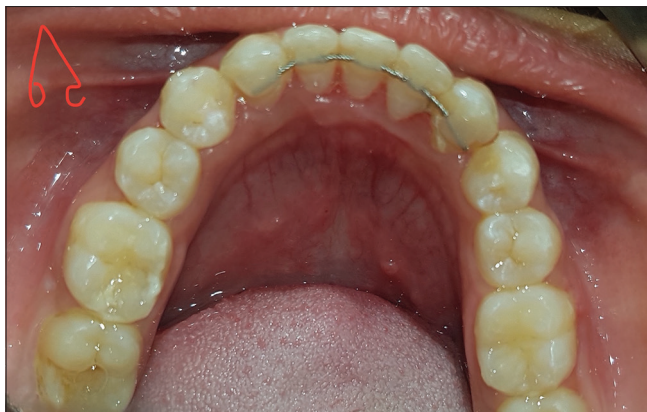

Figure 3: Bonding done ævæ clips removed

Moreover, then the wire is extended to the incisal area and bended linguallly. Markings are done at the area where the fixed lingual retainer is to be given, and round bend facing to the lingual embrasure area is given so that the lingual retainer wire is hold at the desired level by this "V" Retainer clip.

As shown in Figure 1, lingual part of the clip will be longer than the Labial part.

PROCEDURE

The lingual surfaces are etched with the etchant and cleaned with water. After air drying, the bonding agent is applied and cured with ultraviolet (UV) light. The wire is placed and stabilized with "V" retainer clip. A number of clips used varies from 3 to 4. In general, upper and lower arch requires 4 and 3 clips [Figure 2], respectively.

After stabilization, the composite is applied on the lingual surface over the retainer wire and cured with UV light. Excess wire is cut, and the free ends of the wire are secured within the composite material. After fixing the lingual retainer, the "V" retainer clips are removed easily with the wintgart plier [Figure 3].

Chairside time was spent for fabrication of the "V" clip; however if the clinician prefers, they can be customized in the laboratory and kept ready for use.

Advantages

1. Accurate, effective, and predictable
2. Easy to make and cost-effective
3. Wire used is resilient and easy to manipulate
4. Reduces chairside time
5. Less armamentarium needed
6. No laboratory work required
7. No Assistance required.

Disadvantages

Chairside time is needed for construction of the V clips. If the V clips are kept in place for a prolonged duration, it may cause opening of the contact points.

Financial support and sponsorship

Nil.

Conflicts of interest

There are no conflicts of interest.

REFERENCES

1. Bearn DR. Bonded orthodontic retainers: A review. *Am J Orthod Dentofacial Orthop* 1995;108:207-13.
2. Kini V, Patil SM, Jagtap R. Bonded reinforcing materials for esthetic anterior periodontal tooth stabilization: A case report. *Int J Dent Clin* 2011;3:90-1.
3. Lim SM, Hong RK, Park JY. A new indirect bonding technique for lingual retainers. *J Clin Orthod* 2004;38:652-5.
4. Zachrisson BU. Clinical experience with direct-bonded orthodontic retainers. *Am J Orthod* 1977;71:440-8.
5. Gopalan C, Kumar J. A comparative evaluation of the physical properties of two orthodontic archwires. *JIOS* 2016;50:75-82.