

## Case Report

# Orthodontic rehabilitation of an adult patient with pathologic migration and crossbite

### ABSTRACT

The number of adults seeking orthodontic treatment for correction of their malocclusion is increasing. More number of periodontally compromised adults is opting for orthodontic treatment. Periodontal bone loss, pathologic migration, gingival recession, traumatic occlusion, and mobility may be seen in such patients. Interdisciplinary treatment approach is required to effectively manage such cases. Orthodontic treatment can correct traumatic occlusions, correct crowding for better oral hygiene maintenance, and prevent further bone loss, to improve esthetics, function, and stability. The purpose of this article is to highlight the role of orthodontics in correcting traumatic occlusions, aligning teeth in case of pathologic migration, and improving the periodontal status of a periodontally compromised adult.

**Key words:** Adult orthodontics; crossbite; periodontally compromised; traumatic occlusion.

### Introduction

Today, we see more number of adults seeking orthodontic treatment for correction of their malocclusion. The primary motivating factor is the desire to correct their dental esthetics.<sup>[1]</sup> Adults with increased overjet, deep bite, and crowding, whether or not they have previously received orthodontic treatment, have reported significantly lower self-concept ratings than those without malocclusion.<sup>[2]</sup> Malocclusion might negatively interfere with self-satisfaction concerning appearance and accordingly, impair social functioning.<sup>[3]</sup>

A study of adults with skeletal disharmonies had found that more than one-third of the subjects reported that they had experienced substantial distress and personal insecurity caused by their appearance.<sup>[4]</sup>

Orthodontic treatment has a positive effect on the patient.<sup>[5]</sup> An improvement in esthetics because of orthodontic treatment of severe malocclusion improves the oral health-related quality of life.<sup>[6]</sup>


Special attention toward the periodontal health is required in adult patients as they may already be suffering from periodontal health related problems or may be susceptible for the same in future because of their malocclusion.<sup>[7]</sup> Adult orthodontic therapy can provide esthetics and function with satisfactory long-term prognosis provided that the patient is well motivated and responds well to initial periodontal therapy.<sup>[8]</sup> During and after orthodontic treatment, good oral hygiene at home and professional oral hygiene maintenance visits are necessary.<sup>[7]</sup>

Adults with severe malocclusions have severe periodontal problems. Some malocclusions such as deep bite and anterior crossbites are harmful to the periodontium. An anterior deep

**GANESH CHINTHAN, RAMACHANDRA CS<sup>1</sup>, SHAM BHAT<sup>1</sup>, KIRAN NAGARAHALLI<sup>1</sup>, SUSHRUTH SHETTY<sup>1</sup>**

Department of Orthodontics, Kannur Dental College, Kannur, Kerala, <sup>1</sup>Department of Orthodontics, A.E.C.S. Maaruti College of Dental Sciences and Research Centre, Bengaluru, Karnataka, India

**Address for correspondence:** Dr. Ganesh Chintan, 8-83/8, Pragathi Nagar Layout, Pakkaladka, Bajal, Mangalore - 575 027, Karnataka, India.  
E-mail: dr.chintan@gmail.com

Access this article online	
<b>Website:</b> <a href="http://www.orthodrehab.org">www.orthodrehab.org</a>	<b>Quick Response Code</b> 
<b>DOI:</b> 10.4103/2349-5243.192533	

This is an open access article distributed under the terms of the Creative Commons Attribution-NonCommercial-ShareAlike 3.0 License, which allows others to remix, tweak, and build upon the work non-commercially, as long as the author is credited and the new creations are licensed under the identical terms.

**For reprints contact:** [reprints@medknow.com](mailto:reprints@medknow.com)

**How to cite this article:** Chintan G, Ramachandra CS, Bhat S, Nagarahalli K, Shetty S. Orthodontic rehabilitation of an adult patient with pathologic migration and crossbite. *Int J Orthod Rehabil* 2016;7:105-7.

bite strips the gingiva on the palatal aspect of the maxillary incisors, and an anterior crossbite can result in recession and mobility of the lower incisor. Correcting this malocclusion with orthodontic treatment is most likely beneficial for periodontal health.<sup>[9]</sup>

Malocclusions such as crowding and rotations have a low but significant correlation with the plaque, calculus, and gingival inflammation.<sup>[10]</sup> After orthodontic correction of malocclusions, patients show better oral hygiene.<sup>[11]</sup> According to the National Oral Health Survey and Fluoride Mapping (2002–2003), Dental Council of India, New Delhi, 2004, in India, the prevalence of periodontal disease increased with age. The prevalence was 57%, 67.7%, 89.6%, and 79.9% in the age groups 12, 15, 35–44, and 65–74 years, respectively.<sup>[12]</sup>

Thus, adults seeking orthodontic treatment for correction of their malocclusions may already be having periodontal problems of varying severity. The orthodontist and the adult patient must accept the reality of the problem. Periodontal and functional considerations have to be made during diagnosis and treatment planning. However, the goals remain the same, facial esthetics and harmony, healthy teeth and supporting tissues, and functional efficiency and stability.<sup>[13]</sup>

Plaque is the most important factor in the initiation, progression, and recurrence of periodontal problems. Improper maintenance of oral hygiene during orthodontic treatment increases the risk of developing gingival inflammation. There is evidence of increase in the lactobacillus count in the saliva after placement of fixed appliances.<sup>[14]</sup> The primary objective of periodontal therapy is to restore and maintain the health and integrity of the attachment apparatus of the teeth, during and after orthodontic correction.<sup>[15]</sup>

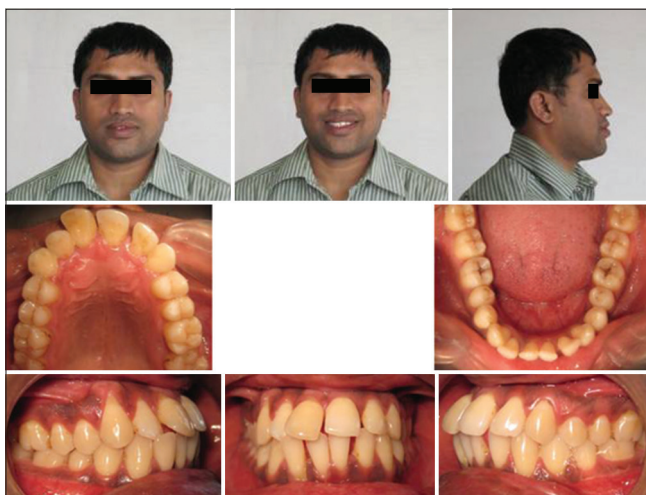

Figure 1: Pretreatment extraoral and intraoral photographs

Following is a case treated with an interdisciplinary approach.

A 29-year-old male patient came with a complaint of irregularly placed upper and lower front teeth and irregularity increasing in the past 1 year [Figure 1]. The patient had no relevant medical history and had visited a dentist with the same complaint 8–10 months back, who had performed oral prophylaxis and had recommended orthodontic treatment for correction of his problem. He was a well motivated and cooperative.

#### Intraoral assessment

On examination, the patient was found to have an Angle's Class I malocclusion on a Class III skeletal base with maxillary, mandibular anterior spacing and crossbite. Chronic generalized marginal gingivitis with localized periodontitis with gingival recession found in relation to 13, 12, 11, 21, 23, 41, and 42 and pathologic migration of the anterior teeth. Grade II mobility of the maxillary right central incisor and mandibular right lateral incisor was seen. Crossbite was seen in relation to 12 and the resulting traumatic occlusion was increasing the gingival recession. The skeletal malocclusion confirmed by a lateral cephalometric radiograph was Class III due to a deficient maxilla. However, the patient never bothered about his appearance, was in fact happy with a prominent looking lower jaw, but was more worried about the increasing irregularity of the anterior teeth.

#### Management

After thorough oral prophylaxis, the patient was advised use of chlorhexidine mouth rinse twice daily. Once gingival health returned to normal, fixed orthodontic treatment was planned to correct the traumatic occlusion due to crossbite and align the teeth that showed pathologic migration and closed the anterior spaces. The patient opted for esthetic brackets.

The preadjusted edgewise appliance with 0.022" McLaughlin, Bennett, Trevisi prescription was used. The lower incisor

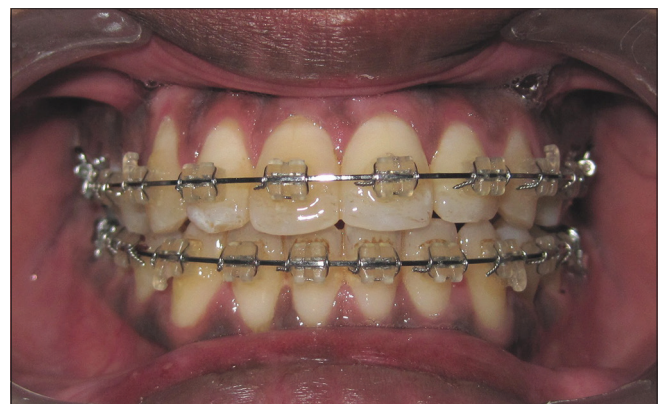

Figure 2: Mid-treatment intraoral photograph

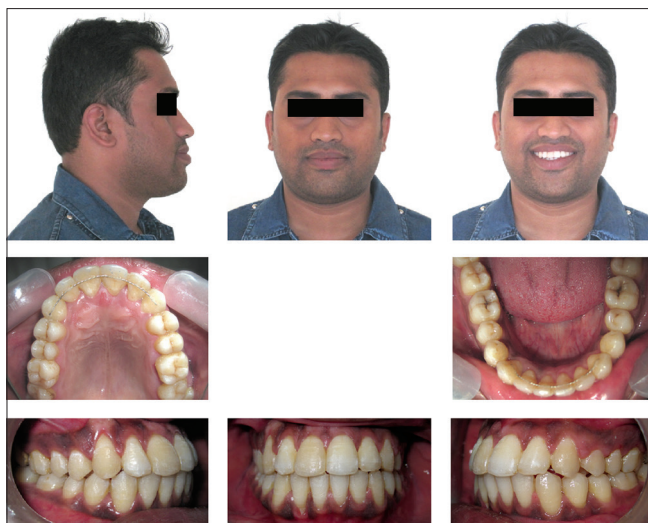

Figure 3: Posttreatment extraoral and intraoral photographs

brackets were inverted during bonding so that the torque would be reversed without changing the tip. This positive torque moved the roots of lower incisors further into the bone rather than away from it [Figure 2]. To keep the forces low, aligning was started with a 0.012" nickel-titanium (Ni-Ti) wire and then progressively increased to 0.014" Ni-Ti, 0.016" Ni-Ti, 0.016" × 0.022" Ni-Ti, 0.017" × 0.025" Ni-Ti, and finally 0.019" × 0.025" stainless steel (SS) wire was used to fill the slot and close residual spaces with an elastic chain. Throughout the treatment, Stainless steel ligature ties were used as plaque accumulates less over Stainless steel ligature ties than elastic modules. During treatment, oral hygiene maintenance by the patient deteriorated which the patient attributed to the increased stress levels at his workplace which did not allow him to concentrate on his oral hygiene. At every appointment, strict oral hygiene maintenance was advised. Scaling was done at intervals of 6 months during the orthodontic treatment period. Once the malocclusion was corrected, finishing and detailing were done. The progression of gingival recession stopped, and periodontal stability was attained. Bonded lingual retainers were placed for retaining the correction achieved and the appliance was debonded. Duration of treatment was about 1 year and 9 months. Few white spot lesions were seen on the teeth. Importance of maintaining the oral hygiene was explained to the patient, and periodic periodontal checkups were recommended. Increased self-confidence was evident posttreatment. This was evident even in comparison of patient's appearance in pretreatment and posttreatment extraoral photographs [Figure 3].

### Declaration of patient consent

The authors certify that they have obtained all appropriate patient consent forms. In the form the patient(s) has/have given his/her/their consent for his/her/their images and other clinical information to be reported in the journal. The patients understand that their names and initials will not be published and due efforts will be made to conceal their identity, but anonymity cannot be guaranteed.

### Financial support and sponsorship

Nil.

### Conflicts of interest

There are no conflicts of interest.

### References

1. McKiernan EX, McKiernan F, Jones ML. Psychological profiles and motives of adults seeking orthodontic treatment. *Int J Adult Orthodon Orthognath Surg* 1992;7:187-98.
2. Helm S, Kreiborg S, Solow B. Psychosocial implications of malocclusion: A 15-year follow-up study in 30-year-old Danes. *Am J Orthod* 1985;87:110-8.
3. Palomares NB, Celeste RK, Oliveira BH, Miguel JA. How does orthodontic treatment affect young adults' oral health-related quality of life? *Am J Orthod Dentofacial Orthop* 2012;141:751-8.
4. Phillips C, Beal KN. Self-concept and the perception of facial appearance in children and adolescents seeking orthodontic treatment. *Angle Orthod* 2009;79:12-6.
5. Varela M, Garcia-Camba JE. Impact of orthodontics on the psychologic profile of adult patients: A prospective study. *Am J Orthod Dentofacial Orthop* 1995;108:142-8.
6. Silvola AS, Varimo M, Tolvanen M, Rusanen J, Lahti S, Pirttiniemi P. Dental esthetics and quality of life in adults with severe malocclusion before and after treatment. *Angle Orthod* 2014;84:594-9.
7. Feng X, Oba T, Oba Y, Moriyama K. An interdisciplinary approach for improved functional and esthetic results in a periodontally compromised adult patient. *Angle Orthod* 2005;75:1061-70.
8. Melsen B, Agerbaek N, Markenstam G. Intrusion of incisors in adult patients with marginal bone loss. *Am J Orthod Dentofacial Orthop* 1989;96:232-41.
9. Bollen AM. Effects of malocclusions and orthodontics on periodontal health: Evidence from a systematic review. *J Dent Educ* 2008;72:912-8.
10. Buckley LA. The relationships between malocclusion, gingival inflammation, plaque and calculus. *J Periodontol* 1981;52:35-40.
11. Zachrisson S, Zachrisson BU. Gingival condition associated with orthodontic treatment. *Angle Orthod* 1972;42:26-34.
12. Shaju JP, Zade RM, Das M. Prevalence of periodontitis in the Indian population: A literature review. *J Indian Soc Periodontol* 2011;15:29-34.
13. Vaden JL, Harris EF, Behrens RG. Adult versus adolescent Class II correction: A comparison. *Am J Orthod Dentofacial Orthop* 1995;107:651-61.
14. Ericsson I, Thilander B. Orthodontic forces and recurrence of periodontal disease. An experimental study in the dog. *Am J Orthod* 1978;74:41-50.
15. Pinho T, Neves M, Alves C. Multidisciplinary management including periodontics, orthodontics, implants, and prosthetics for an adult. *Am J Orthod Dentofacial Orthop* 2012;142:235-45.